
From neuronal inclusions to neurodegeneration: neuropathological investigation of a transgenic mouse model of Huntington's disease

Stephen W. Davies, Turmaine Mark, Barbara A. Cozens, Aysha S. Raza, Amarbirpal Mahal, Laura Mangiarini and Gillian P. Bates

Phil. Trans. R. Soc. Lond. B 1999 **354**, 971-979

doi: 10.1098/rstb.1999.0448

References

Article cited in:

<http://rstb.royalsocietypublishing.org/content/354/1386/971#related-urls>

Email alerting service

Receive free email alerts when new articles cite this article - sign up in the box at the top right-hand corner of the article or click [here](#)

To subscribe to *Phil. Trans. R. Soc. Lond. B* go to: <http://rstb.royalsocietypublishing.org/subscriptions>

From neuronal inclusions to neurodegeneration: neuropathological investigation of a transgenic mouse model of Huntington's disease

Stephen W. Davies^{1*}, Mark Turmaine¹, Barbara A. Cozens¹, Aysha S. Raza¹, Amarbirpal Mahal², Laura Mangiarini² and Gillian P. Bates²

¹*Department of Anatomy and Developmental Biology, University College London, Gower Street, London WC1E 6BT, UK*

²*Medical and Molecular Genetics, GKT Medical and Dental School, King's College, 8th Floor, Guy's Tower, London SE1 9RT, UK*

Huntington's disease (HD) is an inherited progressive neurodegenerative disease caused by the expansion of a polyglutamine repeat sequence within a novel protein. Recent work has shown that abnormal intranuclear inclusions of aggregated mutant protein within neurons is a characteristic feature shared by HD and several other diseases involving glutamine repeat expansion. This suggests that in each of these disorders the affected nerve cells degenerate as a result of these abnormal inclusions. A transgenic mouse model of HD has been generated by introducing exon 1 of the HD gene containing a highly expanded CAG sequence into the mouse germline. These mice develop widespread neuronal intranuclear inclusions and neurodegeneration specifically within those areas of the brain known to degenerate in HD. We have investigated the sequence of pathological changes that occur after the formation of nuclear inclusions and that precede neuronal cell death in these cells. Although the relation between inclusion formation and neurodegeneration has recently been questioned, a full characterization of the pathways linking protein aggregation and cell death will resolve some of these controversies and will additionally provide new targets for potential therapies.

Keywords: Huntington's disease; neurodegeneration; neuronal intranuclear inclusions; transgenic mouse; cell death; neuropathology

1. INTRODUCTION

Huntington's disease (HD) is one of eight progressive inherited neurodegenerative disorders caused by a common genetic mechanism (reviewed in Harper 1996). In addition to HD the seven other diseases comprise spinal and bulbar muscular atrophy (SBMA, also known as Kennedy disease), dentatorubral–pallidoluysian atrophy (DRPLA), and five different spinocerebellar ataxias (SCA-1, SCA-2, SCA-3 (also known as Machado–Joseph disease), SCA-6 and SCA-7). In each disease the expansion of a CAG trinucleotide repeat within unrelated genes gives rise to an expanded sequence of glutamine residues (polyQ) within the corresponding protein. Disease generally occurs when the number of glutamine residues exceeds 35–40, suggesting that the disease is caused directly by the expanded glutamine tracts rather than by an abnormal function of the protein with the repeats. Perutz *et al.* (1994) proposed that expanded glutamine repeats might self-associate into aggregates with a β -pleated sheet structure. However, until 1997 such structures had not been reliably observed in any of these polyQ expansion diseases.

Ever since the identification of the HD gene in 1993 (Huntington's Disease Collaborative Research Group

1993), attempts have been made to model HD in transgenic mice (see Sathasivam *et al.*, this issue; Bates *et al.* 1998). Several lines of mice with a neurological phenotype reminiscent of the human disease that they seek to model have been produced by expressing a construct comprising exon 1 of human huntingtin with (CAG)115 to (CAG)156 repeats under the control of the human huntingtin promoter (Mangiarini *et al.* 1996). Immunocytochemical staining of sections from the brains of these mice with antibodies specific for the N-terminus of huntingtin and with anti-ubiquitin antibodies revealed the presence of large numbers of neuronal intranuclear inclusions (NIIs) (Davies *et al.* 1997). Ultrastructurally these inclusions seem to have a diameter of *ca.* 2 μ m, to have a pale granular and fibrous appearance and to be devoid of an encircling membrane. Experiments *in vitro* (see Hollenbach *et al.*, this issue) have further shown that the transgene-encoded huntingtin protein assembles into fibrils that show birefringence when stained with Congo red, and is indicative of a β -pleated sheet structure (Scherzinger *et al.* 1997).

After their discovery in transgenic mice, NIIs have now been identified in post-mortem HD brain (DiFiglia *et al.* 1997; Becher *et al.* 1998; Gourfinkel-An *et al.* 1998). They were found to be immunoreactive with antibodies directed against the N-terminus of huntingtin and with anti-ubiquitin antibodies, but not with antibodies directed

*Author for correspondence (s.w.davies@ucl.ac.uk).

against the middle region or the C-terminus of huntingtin. This suggested that it is a truncated N-terminal portion of huntingtin that accumulates in the inclusions. This was supported by the finding that an N-terminal fragment of *ca.* 40 Da is enriched in nuclear fractions from HD brain (DiFiglia *et al.* 1997). A nuclear localization of huntingtin protein is unlike the exclusively cytoplasmic localization found in previous studies of mouse, monkey or human brain (Bhide *et al.* 1996; Gutekunst *et al.* 1995; DiFiglia *et al.* 1995; Trotter *et al.* 1995), although a single report has documented the localization of huntingtin within the nucleus of mouse embryonic fibroblasts and mouse neuroblastoma cells (De Rooij *et al.* 1996). A gain of function, conferred on the N-terminal fragment of huntingtin by the pathological expansion of the polyQ sequence, therefore seems to be entry into (and aggregation within) the neuronal nucleus. The ultrastructural appearance of NIIs in HD (DiFiglia *et al.* 1997) was found to be similar to those found in the HD transgenic mouse; the inclusions were highly reminiscent of structures found in an earlier ultrastructural study of biopsy samples of HD brain (Roizin *et al.* 1979).

The discovery of NIIs in Huntington's disease prompted studies investigating their presence in other diseases due to the expansion of glutamine repeats. Within the past 18 months, inclusions of aggregated protein have been found in the neuronal nucleus in several other polyQ diseases.

In SCA-3 the 42 Da cytoplasmic protein ataxin-3 is found in ubiquitinated nuclear inclusions within those nerve cells that are known to degenerate in the disease (Paulson *et al.* 1997*a,b*; Schmidt *et al.* 1998). Ataxin-1 is an 87 Da nuclear protein that contains expanded glutamine repeats in the disease SCA-1. In SCA-1 transgenic mice, the wild-type human protein localizes to several nuclear structures 0.5 μ m in diameter, whereas the protein with an expanded polyQ sequence is found in a single ubiquitinated nuclear inclusion 2 μ m in diameter (Skinner *et al.* 1997). In post-mortem brain of patients with SCA-1, ubiquitinated 2 μ m inclusions were present in neuronal nuclei in the regions of the brain affected by the disease. Similarly in the spinocerebellar ataxia SCA-7, caused by the expansion of a polyQ sequence in a 95 Da protein called ataxin-7, NIIs 3 μ m in diameter were observed in neurons specifically affected by the disease (Holmberg *et al.* 1998). NIIs were immunoreactive with an antibody specific for long polyQ stretches, and were also stained with an anti-ubiquitin antibody.

DRPLA is caused by an expanded polyQ sequence in a 124 Da protein termed atrophin-1. In patients with DRPLA, neurons in the dentate nucleus of the cerebellum have been found to contain NIIs 2 μ m in diameter and are of a similar ultrastructural appearance to those found in HD (Becher *et al.* 1998; Igarishi *et al.* 1998; Hayashi *et al.* 1998). These inclusions contain both atrophin-1 and ubiquitin.

Spinal and bulbar muscular atrophy (SBMA) is caused by the expansion of a polyQ sequence in the 104 Da androgen receptor. In patients with SBMA, spinal and bulbar motor neurons contain ubiquitinated NIIs 1–5 μ m in diameter (Li *et al.* 1998*a,b*). They are immunoreactive with antibodies against the N-terminal region of the androgen receptor containing the polyQ sequence, but

not with antibodies against the C-terminal region. In addition to these neuronal NIIs, immunoreactive inclusions can be found in several peripheral tissues (Li *et al.* 1998*b*). Both the cleavage and location within peripheral tissues are similar to results found in the HD brain (DiFiglia *et al.* 1997) and the transgenic mouse model of HD, respectively (see Sathasivam *et al.*, this issue).

These findings indicate that the formation of NIIs is the pathogenic mechanism underlying trinucleotide repeat disorders with expanded glutamine repeats (Davies *et al.* 1998; Lieberman *et al.* 1998). They also suggest that glutamine tracts over a certain length might be inherently toxic to neurons, irrespective of the proteins in which they are located. This has been tested in transgenic mice with a 146 glutamine repeat stretch inserted into the hypoxanthine phosphoribosyltransferase protein (Ordway *et al.* 1997). These mice developed a neurological phenotype that was preceded by the appearance of numerous ubiquitinated intranuclear inclusions in a number of regions of the brain. Expression of either C-terminal fragments of ataxin-3 or N-terminal fragments of huntingtin containing expanded polyQ sequences in neurons in *Drosophila* have also been shown to lead to the formation of NIIs (Warrick *et al.* 1998; Jackson *et al.* 1998).

We have reviewed briefly the wealth of recent data that have documented the formation of NIIs in both human disease and transgenic animal models. We shall now describe the temporal sequence of neuropathological changes that occur, after the appearance of NIIs, within neurons of the brain of HD transgenic mice (see Sathasivam *et al.* (this issue) for a full description of the various lines of R6 transgenic mice). We relate these changes to those found in the human HD post-mortem brain.

2. NIIs AND NUCLEAR CHANGES

NIIs can first be detected in sections of brain from R6 transgenic mice with antibodies against the N-terminal region of huntingtin. Initially the nucleus contains a diffuse reaction product consisting of several discrete aggregates of increased staining. Additionally there is increased huntingtin immunoreactivity associated with nuclear pores. Reaction product from immunoreactivity can be found on either face of the pore as well as traversing the lumen. This diffuse nuclear staining condenses, over time, to form a single NII with a loss of immunoreactivity from the surrounding nucleus. These single NIIs can then be detected with antibodies against ubiquitin (Davies *et al.* 1997); some time later they can be detected by conventional transmission electron microscopic studies. The initial stages of the formation of NIIs cannot be recognized as a discrete structure by electron microscopy. The initial protein components of the NIIs are subsequently added to, as inclusions are later found to be immunoreactive for the 20S proteasome and the molecular chaperone HDJ-2/HSDJ (B. A. Cozens and S. W. Davies, unpublished data; Cummings *et al.* 1998). Sequestration of the proteasome has been found within cytoplasmic inclusions in several neurodegenerative diseases (Ii *et al.* 1997). The high concentrations of the proteasome found in the neuronal nucleus (Mengual *et al.* 1996) suggest that proteasome components might become trapped in the intranuclear inclusions, thereby

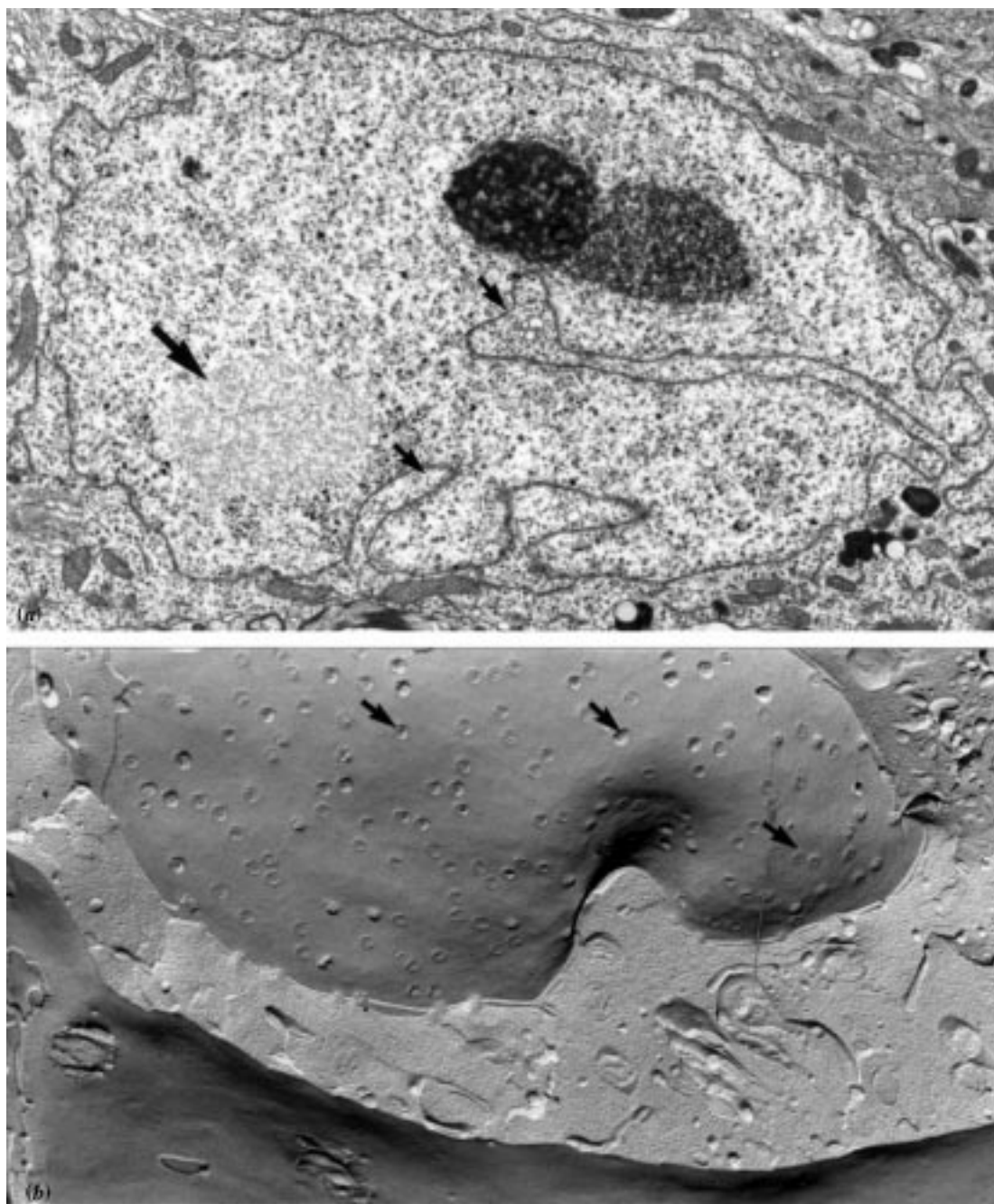


Figure 1. Morphology of the neuronal nucleus in the HD transgenic mouse. (a) Transmission electron micrograph of a striatal neuron exhibiting prominent indentation of the nuclear membrane (small arrows) and containing a pale-staining granular and fibrous NII, 3 μm in diameter (large arrow in bottom left-hand corner). A more darkly stained nucleolus is also present (top right-hand corner). (b) Freeze–fracture of a nuclear membrane of a striatal neuron from an R6/2 transgenic mouse. Note the density of nuclear pores (small arrows). Magnification $\times 10\,000$.

contributing to the demise of the neuron. After the formation of an NII, the nucleolus enlarges progressively (Davies *et al.* 1997). The appearance of an NII within a neuronal nucleus is followed by the invagination of the nuclear membrane (figure 1); this can often be quite marked, with the formation of labyrinthine membrane complexes in cerebellar Purkinje cells (S. W. Davies, unpublished data). A similar feature of nuclear membrane indentation in cerebellar Purkinje cells, after the formation of NIIs, has been observed in a transgenic mouse model of SCA-1 (Skinner *et al.* 1997).

Invagination of the nuclear membrane seems to be accompanied by an increase in the density of nuclear pores in both conventional transmission electron microscopy and in freeze–fracture preparations (figure 1). The increased number of nuclear pores is not associated with any peripheral clumping of the chromatin adjacent to the nuclear membrane, because although chromatin forms dispersed aggregates throughout the nucleus, it does not marginate to the periphery. These prominent ultrastructural changes within the neuronal nucleus (formation of NIIs, nuclear membrane invagination, condensation of

chromatin and increased nuclear pore density) have all been reported to occur in post-mortem HD brain (see Davies *et al.* 1997).

3. DYSTROPHIC NEURITE INCLUSIONS

In addition to the nuclear inclusions we find inclusions of seemingly identical granular and fibrous structures within dystrophic neuronal processes (Bates *et al.* 1998). These dystrophic neurite inclusions (DNIs) occur within neurites, myelinated axons, vesicle containing preterminal processes or nerve terminals. Immunocytochemical studies show that these inclusions are, similarly to nuclear inclusions, composed of huntingtin and ubiquitin (figure 2). The ultrastructural appearance of DNIs in the transgenic mouse are similar to the DNIs originally described by DiFiglia *et al.* (1997) in HD post-mortem tissue. DNIs are few in number and appear only some time after NIIs in the transgenic mouse brain. This is the first description of the presence of huntingtin immunoreactivity in inclusions in dystrophic neurites in a transgenic mouse model of HD. DNIs have not been reported in SBMA, DRPLA or any of the spinocerebellar ataxias.

4. GLIAL INTRANUCLEAR INCLUSIONS

In addition to the more prevalent NIIs and DNIs we additionally observe nuclear inclusions within glial cells. Glial intranuclear inclusions can be found within astrocytes, oligodendrocytes and microglia of the R6/2 and R6/1 lines of transgenic mice (figure 3); however, these structures are extremely rare. We have identified only a few examples of these structures in neuroglial cells. GII have not to our knowledge been described in post-mortem human HD, DRPLA, SBMA or SCA brain, although it is of interest that inclusions composed of α -synuclein have been reported in nuclei of oligodendrocytes in post-mortem brain in multiple system atrophy (Papp & Lantos 1994; Spillantini *et al.* 1998).

5. ACCUMULATION OF LIPOFUSCIN

After the formation of NIIs and the other ultrastructural changes within the nucleus and cytoplasm described above, we also see the appearance of frequent accumulations of lipofuscin within the cytoplasm of neurons (figure 4*d*; Davies *et al.* 1997). This can be seen even in juvenile mice from 12 weeks old (R6/2 line). Lipofuscin accumulation within neurons is usually associated with normal ageing but has also been found in post-mortem HD brain (Vonsattel & DiFiglia 1998).

6. NEURONAL SHRINKAGE

The brains of R6/2 transgenic mice are 19% smaller by weight than those of their littermates (Davies *et al.* 1997). This decrease in size is progressive; shrinkage is not apparent until six weeks of age, and occurs in all regions of the brain. Changes within the brain precede any of the changes that occur in body weight (Davies *et al.* 1997), although this might not remain true when individual tissues are examined (see Sathasivam *et al.*, this issue). We have begun a morphometric analysis of the

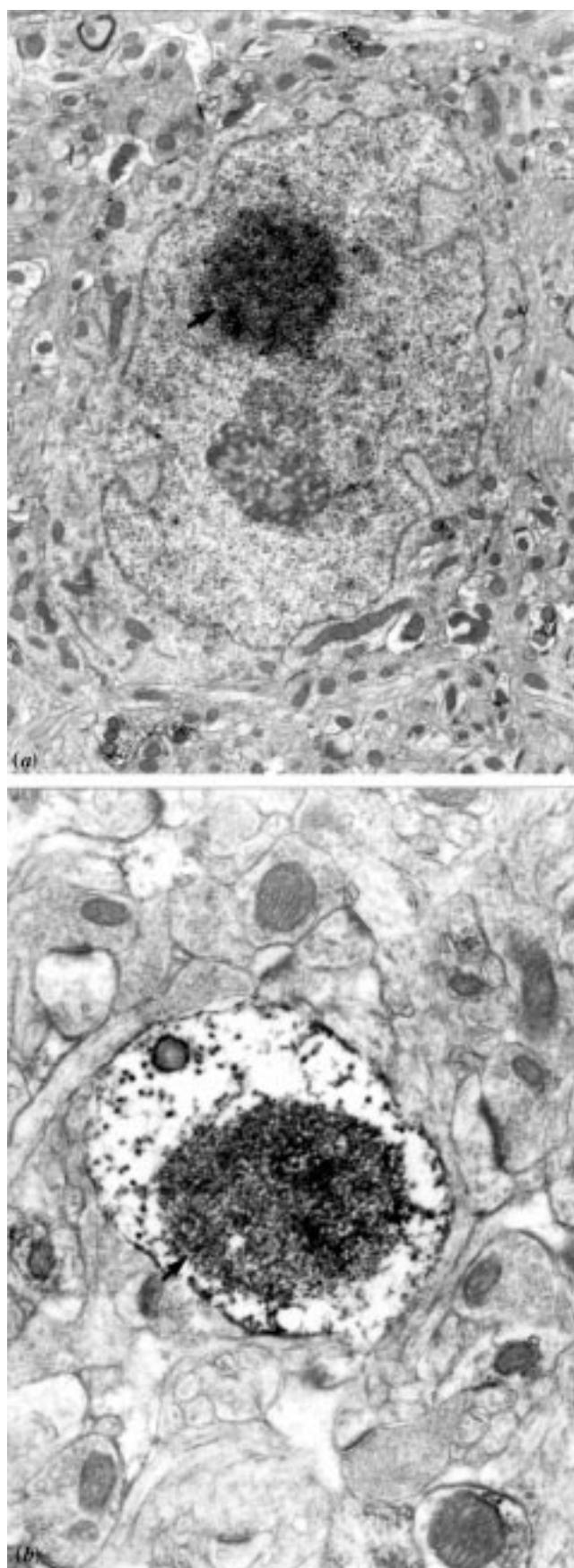


Figure 2. Comparison of nuclear and neurite, huntingtin-immunoreactive, inclusions. A dense granular reaction product defines the area of huntingtin immunoreactivity arrowed within the nucleus (*a*) and dystrophic neurite (*b*). Magnification (*a*) $\times 10\,000$ and (*b*) $\times 50\,000$.

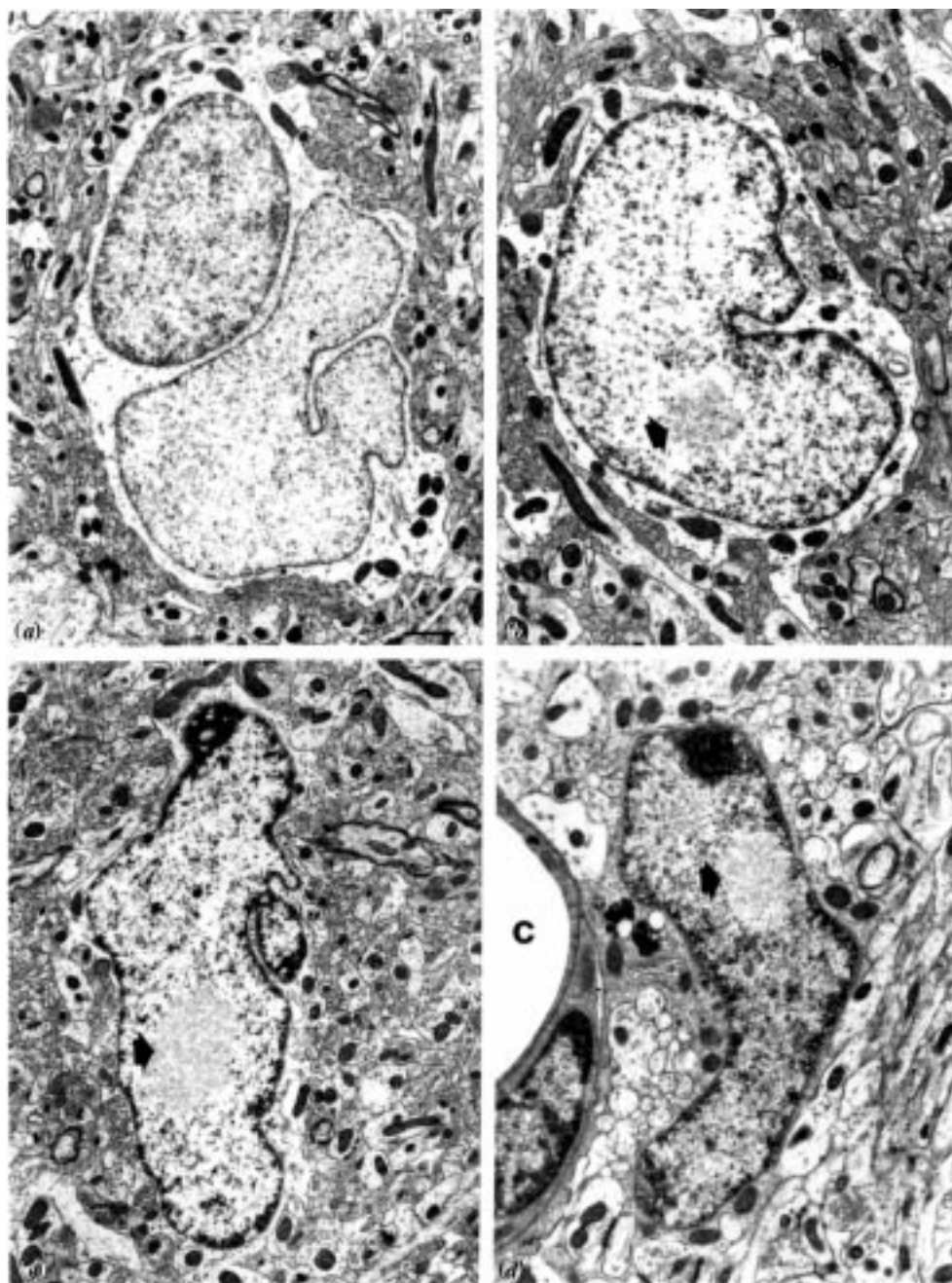


Figure 3. Nuclear inclusions in neuroglial cells. An astrocyte nucleus from control mouse brain (*a*) is compared with astrocyte nuclei (*b*, *c*) and the nucleus of a microglial cell (*d*). The glial intranuclear inclusions are arrowed in (*b*–*d*). In (*d*) the profile labelled *c* is a small capillary. Scale bar, 500 nm.

transgenic mouse brain and find that a marked atrophy occurs in neurons of both neocortex and striatum beginning at around six weeks of age (A. S. Raza and S. W. Davies, unpublished data). This is progressive until 13 weeks of age. Vonsattel & DiFiglia (1998) have commented that neurons in the HD post-mortem brain 'contain more lipofuscin and may be smaller than usually expected'; similar observations have been made in the other polyQ diseases.

7. NEURODEGENERATION

Within the anterior cingulate cortex, dorsal striatum and Purkinje cells of the cerebellar vermis we can find degenerating neurons (Turmaine *et al.* 1999). These cells

are of a distinctive darkened appearance and can best be studied either by light microscopy in semi-thin sections stained with toluidine blue or by electron microscopy in thin sections stained with osmium and lead acetate. Neurons within these areas of the brain are darkly stained in either preparation and exhibit both nuclear and cytoplasmic condensation and clumping of chromatin. Subcellular organelles, including mitochondria, seem intact although there is some swelling of the lumen of the Golgi network. The plasma membrane is ruffled, giving a scalloped appearance to the darkened cell. All degenerating cells contain a distinctive NII and exhibit extensive invagination of the nuclear membrane; however, there is no fragmentation of either the cytoplasm or the nucleus. We cannot find any characteristic apoptotic bodies. A

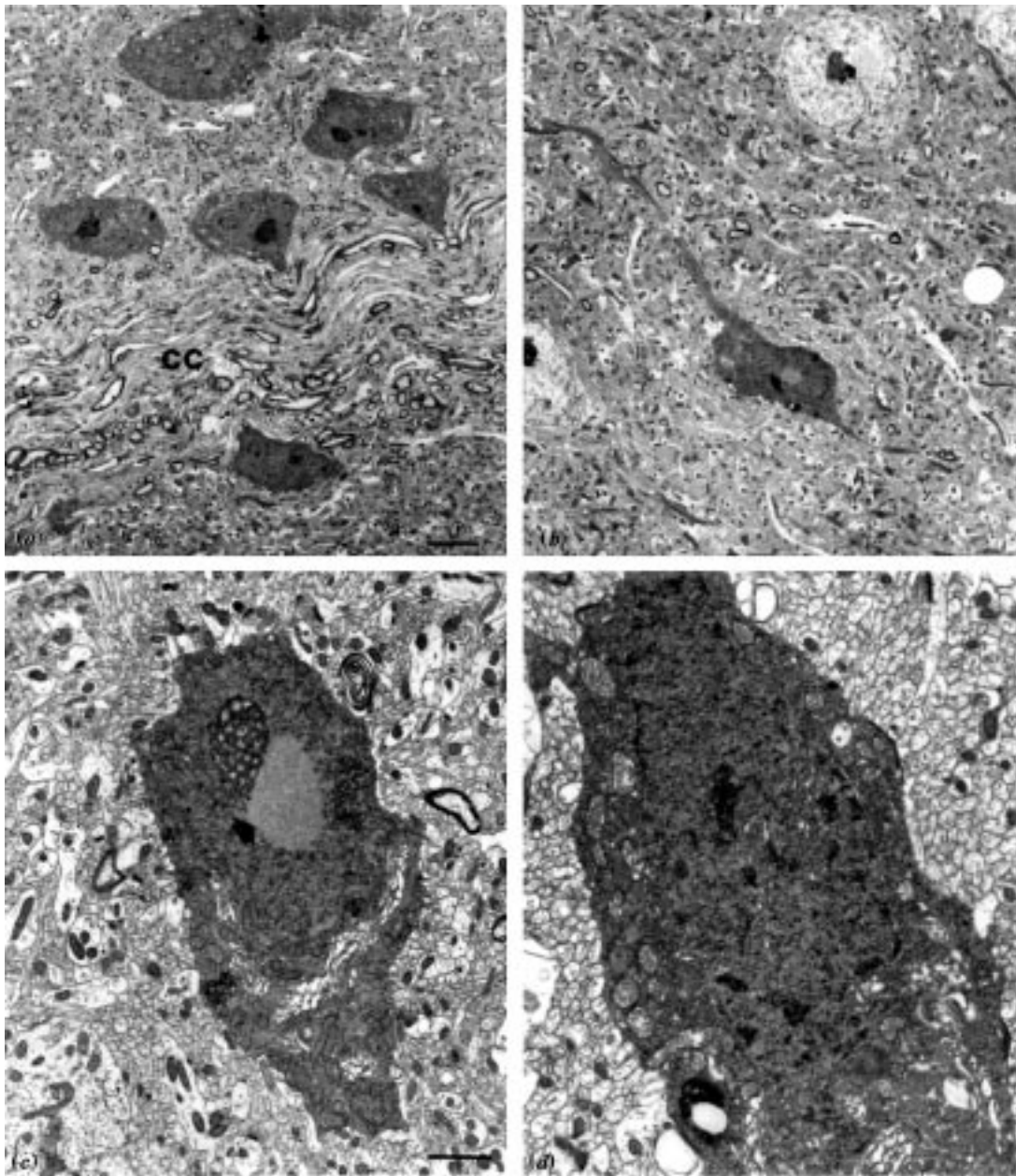


Figure 4. Degenerating neurons within the striatum and cortex in the R6/2 HD transgenic mouse. (a) Degenerating neurons located on either side of the corpus callosum (cc); (b–d) degenerating cells are shown at higher magnification with the NIIs arrowed. Scale bars, (a) 5 μ m and (c) 1.5 μ m.

detailed analysis of the number of neurons degenerating within the anterior cingulate cortex suggests that degenerating cells persist in this darkened atrophic form for several weeks.

We have repeatedly tried to identify DNA fragmentation within degenerating neurons by labelling them with the terminal deoxynucleotidyl transferase-mediated (TdT) deoxyuridine triphosphate (dUTP)-biotin nick end labelling (TUNEL) method for the determination of DNA strand breaks *in situ*, but we were unable to find any labelling of these neurons (Turmaine *et al.* 1999).

A uniform ultrastructural appearance of degenerating neurons within defined areas in the brains of HD transgenic mice prompted us to look within these same areas in post-mortem HD brain. We again found dark degenerating neurons, of identical ultrastructural appearance to

those found in the transgenic mouse brain. These cells, containing NIIs, were never found to be fragmented into apoptotic bodies nor to show blebbing of the nucleus or cytoplasm.

8. THE GLIAL RESPONSE

Neurons undergoing dark cell degeneration are eventually surrounded and penetrated by the processes of adjacent astrocytes. These neuroglial cells are similar in appearance to immature astrocytes: they lack prominent glial filaments, have a large pale irregular-shaped nucleus and have numerous small mitochondria. The ultrastructural feature of a lack of glial filaments probably explains the absence of glial fibrillary acidic protein immunoreactivity (GFAP) in immunocytochemical

investigations seeking reactive astrocytes in the transgenic mouse brain. We can find no inflammatory response and no instance of engulfment of fragmented degenerating neurons by macrophages. Rapid engulfment of fragmented cells is another cardinal feature of cell death by apoptosis (Kerr *et al.* 1972; Wyllie *et al.* 1980).

9. DISCUSSION

The formation of an intranuclear inclusion within a neuron is followed by a defined series of morphological changes, initially within the nucleus and later within the cytoplasm. These can eventually lead to the death of specific populations of cells. Neurons undergoing degeneration do so by a characteristic process that is dissimilar to the well-documented processes of either apoptosis or necrosis. All of these changes that we have so far identified in the brains of transgenic mice, expressing exon 1 of the human HD gene containing an expanded glutamine repeat, have similarly been found in the human HD brain.

The initial stages of protein aggregation, well defined *in vitro* (Scherzinger *et al.* 1997), have not been fully characterized *in vivo*. The development of an NII, recognizable in the electron microscope, clearly requires the recruitment of many additional proteins. We currently know the identity of a few of these: the subunits of the 20S proteasome and associated 19S and 11S activator complexes and the molecular chaperones HDJ-2/HSDJ have been identified in nuclear inclusions in transgenic mouse models and in post-mortem brain of both SCA-1 and HD (Cummings *et al.* 1998; B. A. Cozens and S. W. Davies, unpublished data).

Once fully formed, NIIs seem to provoke a wide spectrum of pathological changes within the cell. These include the complex series of nuclear and cytoplasmic changes that we have described. Within the brain of the HD transgenic mouse, specific populations of neurons eventually die; importantly, these are the same populations of cells that degenerate in juvenile-onset HD (Vonsattel *et al.* 1985; Vonsattel & DiFiglia 1998; Ross *et al.* 1997; Robitaille *et al.* 1997; Young 1998). Thus significant pathological change can be found not only in the striatum (Vonsattel *et al.* 1985) but additionally in the cerebellum (Ross *et al.* 1997; Vonsattel & DiFiglia 1998; Young 1998) and in the cortex of the frontal lobes (Monte *et al.* 1988; Sotrel *et al.* 1991; Jackson *et al.* 1995). The mechanism of cell death is unusual: degenerating neurons lack the classical features that characterize either necrosis or apoptosis (Kerr *et al.* 1972; Wyllie *et al.* 1980; Clarke 1990). The progressive atrophy of the cell with condensation of the nucleus and cytoplasm is unlike necrosis, but reminiscent of apoptosis. However, it is significant that despite our observation that most of the pathological changes occur in the nucleus, the defining nuclear changes of apoptosis are not found (figure 4).

The nuclear events of apoptosis begin with the collapse of the chromatin against the nuclear periphery and into one or a few large clumps within the nucleus. The chromatin becomes progressively more condensed, whereas the nuclear envelope remains morphologically intact. In many cases the entire nucleus condenses into a single dense ball, whereas in others the chromatin buds

into smaller balls resembling a bunch of grapes, with each 'grape' surrounded by nuclear membrane (Earnshaw 1995). Changes in the chromatin are accompanied by two changes in the nuclear envelope. The nuclear pores re-distribute by sliding away from the surface of the condensed chromatin domains and accumulating in the regions between them, and the nuclear lamina disassembles. None of these ultrastructural changes can be found in the nuclei of degenerating neurons in the HD transgenic mouse.

A defining feature of the changes that occur in the chromatin in apoptosis is the formation of oligosomal fragments that can be labelled by the TUNEL method. However, we cannot find any evidence of fragmentation of the DNA in this manner. This is in contrast to the reports that have documented TUNEL-positive staining of both glia and neurons in post-mortem HD brain (Portera-Cailliau *et al.* 1995; Brannon Thomas *et al.* 1995; Dragunow *et al.* 1995). However, TUNEL-positive profiles in post-mortem tissue are notoriously difficult to interpret (Lucassen *et al.* 1997). Finally, apoptotic neurons are rapidly engulfed (within days) and phagocytosed by macrophages, whereas the degenerating neurons that we have described persist for long periods (several weeks) and are eventually ensheathed by astrocytic, not microglial, processes. We conclude that this slow pathological process, leading to neuronal death, is different from either of the mechanisms of cell death described previously.

The transgenic mice that we have reported (Mangiarini *et al.* 1996; Davies *et al.* 1997) have helped to elucidate the pathological features of HD. The results presented suggest that these mice demonstrate all of the key pathological features of the disease. They provide us with a unique opportunity to test novel therapeutic agents and to elucidate further the pathway from protein aggregation to neurodegeneration (Goedert *et al.* 1998). This novel progressive non-apoptotic process still remains to be fully characterized.

This work was supported by grants from the Wellcome Trust, the Huntington's Disease Society of America and the Hereditary Disease Foundation.

REFERENCES

- Bates, G. P., Mangiarini, L. & Davies, S. W. 1998 Transgenic mice in the study of polyglutamine repeat expansion diseases. *Brain Pathol.* **8**, 699–714.
- Becher, M. W., Kotzok, J. A., Sharp, A. H., Davies, S. W., Bates, G. P., Price, D. L. & Ross, C. A. 1998 Intranuclear neuronal inclusions in Huntington's disease and dentatorubral and pallidolusian atrophy: correlation between the density of inclusions and IT15 CAG triplet repeat length. *Neurobiol. Dis.* **4**, 387–398.
- Bhide, P. G., Day, M., Sapp, E., Schwarcz, C., Sheth, A., Kim, J., Young, A. B., Penney, J., Golden, J., Aronin, N. & DiFiglia, M. 1996 Expression of normal and mutant huntingtin in the developing brain. *J. Neurosci.* **16**, 5523–5535.
- Brannon Thomas, L., Gates, D. J., Richfield, E. K., O'Brien, T. F., Schweitzer, J. B. & Steindler, D. A. 1995 DNA end labelling (TUNEL) in Huntington's disease and other neuropathological conditions. *Exp. Neurol.* **133**, 265–272.
- Clarke, P. G. H. 1990 Developmental cell death: morphological diversity and multiple mechanisms. *Anat. Embryol.* **181**, 195–213.

- Cummings, C. J., Mancini, M. A., Antalffy, B., De Franco, D. B., Orr, H. T. & Zoghbi, H. Y. 1998 Chaperone suppression of aggregation and altered subcellular proteasome localisation imply protein misfolding in SCAL. *Nature Genet.* **19**, 148–154.
- Davies, S. W., Turmaine, M., Cozens, B. A., DiFiglia, M., Sharp, A. H., Ross, C. A., Scherzinger, E., Wanker, E. E., Mangiarini, L. & Bates, G. P. 1997 Formation of neuronal intranuclear inclusions underlies the neurological dysfunction in mice transgenic for the HD mutation. *Cell* **90**, 537–548.
- Davies, S. W., Beardsall, K., Turmaine, M., DiFiglia, N., Aronin, N. & Bates, G. P. 1998 Neuronal intranuclear inclusions (NII), the common neuropathology of triplet repeat disorders with polyglutamine repeat expansions. *Lancet* **351**, 131–133.
- de la Monte, S. M., Vonsattel, J.-P. G. & Richardson, E. P. 1988 Morphometric demonstration of atrophic changes in the cerebral cortex, white matter and neostriatum in Huntington's disease. *J. Neuropathol. Exp. Neurol.* **47**, 516–525.
- De Rooij, K. E., Dorsman, J. C., Smoor, M. A., den Dunnen, J. T. & Van Ommen, G.-J. B. 1996 Subcellular localisation of the Huntington's disease gene product in cell lines by immunofluorescence and biochemical subcellular fractionation. *Hum. Mol. Genet.* **5**, 1093–1099.
- DiFiglia, M. (and 11 others) 1995 Huntingtin is a cytoplasmic protein associated with vesicles in human and rat brain neurons. *Neuron* **14**, 1075–1081.
- DiFiglia, M., Sapp, E., Chase, K. O., Davies, S. W., Bates, G. P., Vonsattel, J. P. & Aronin, N. 1997 Aggregation of huntingtin in neuronal intranuclear inclusions and dystrophic neurites in brain. *Science* **277**, 1990–1993.
- Dragunow, M., Faull, R. L. M., Lawlor, P., Beihartz, E. J., Singleton, K., Walker, E. B. & Mee, E. 1995 *In situ* evidence for DNA fragmentation in Huntington's disease striatum and Alzheimer's disease temporal lobes. *Clin. Neurosci. Neuropathol.* **6**, 1053–1057.
- Earnshaw, W. C. 1995 Nuclear changes in apoptosis. *Curr. Opin. Cell Biol.* **7**, 337–343.
- Goedert, M., Spillantini, M. G. & Davies, S. W. 1998 Filamentous nerve cell inclusions in neurodegenerative diseases. *Curr. Opin. Neurobiol.* **8**, 619–632.
- Gourfinkel-An, I., Cancel, G., Duyckaerts, C., Faucheaux, B., Hauw, J.-J., Trotter, Y., Brice, A., Agid, Y. & Hirsch, E. C. 1998 Neuronal distribution of intranuclear inclusions in Huntington's disease with adult onset. *NeuroReport* **9**, 1823–1826.
- Gutekunst, C.-A., Levey, A. I., Heilman, C. J., Whalley, W. L., Yi, H., Nash, N. R., Rees, H. D., Madden, J. J. & Hersch, S. M. 1995 Identification and localisation of huntingtin in brain and human lymphoblastoid cell lines with antifusion protein antibodies. *Proc. Natl Acad. Sci. USA* **92**, 8710–8714.
- Harper, P. S. 1996 *Huntington's disease. 2. Major problems in neurology*, vol. 31. London: W. B. Saunders.
- Hayashi, Y. (and 10 others) 1998 Hereditary dentatorubral-pallidolusian atrophy: detection of widespread ubiquitinated neuronal and glial intranuclear inclusions in the brain. *Acta Neuropathol.* **96**, 547–552.
- Holmberg, M. (and 10 others) 1998 Spinocerebellar ataxia 7 (SCA7): a neurodegenerative disorder with neuronal intranuclear inclusions. *Hum. Mol. Genet.* **7**, 913–918.
- Huntington's Disease Collaborative Research Group 1993 A novel gene containing a trinucleotide repeat that is unstable on Huntington's disease chromosomes. *Cell* **72**, 971–983.
- Igarashi, S. (and 18 others) 1998 Suppression of aggregate formation and apoptosis by transglutaminase inhibitors in cells expressing truncated DRPLA protein with an expanded polyglutamine stretch. *Nature Genet.* **18**, 111–117.
- Ii, K., Itoh, H., Tanaka, K. & Hirano, A. 1997 Immunocytochemical localisation of the proteasome in ubiquitinated structures in neurodegenerative diseases and the elderly. *J. Neuropathol. Exp. Neurol.* **56**, 125–131.
- Jackson, G. R., Salecker, I., Dong, X., Yao, X., Arnheim, N., Faber, P. W., MacDonald, M. E. & Zipursky, S. L. 1998 Polyglutamine-expanded human huntingtin transgenes induce degeneration of *Drosophila* photoreceptor neurons. *Cell* **21**, 633–642.
- Jackson, M., Gentleman, S., Lennox, G., Ward, L., Gray, T., Randall, K., Morell, K. & Lowe, J. 1995 The cortical neuritic pathology of Huntington's disease. *Neuropathol. Appl. Neurobiol.* **21**, 18–26.
- Kerr, J. F. R., Wyllie, A. H. & Currie, A. R. 1972 Apoptosis: a basic biological phenomenon with wide ranging implications in tissue kinetics. *Br. J. Cancer* **26**, 239–257.
- Li, M., Miwa, S., Kobayashi, Y., Merry, D. E., Yamamoto, M., Tanaka, F., Doyu, M., Hashizume, Y., Fischbeck, K. H. & Sobue, G. 1998a Nuclear inclusions of the androgen receptor protein in spinal and bulbar muscular atrophy. *Ann. Neurol.* **44**, 249–254.
- Li, M., Nakagomi, Y., Kobayashi, Y., Merry, D. E., Tanaka, F., Doyu, M., Mitsume, T., Hashizume, Y., Fischbeck, K. H. & Sobue, G. 1998b Nonneuronal nuclear inclusions of androgen receptor protein in spinal and bulbar muscular atrophy. *Am. J. Pathol.* **153**, 695–701.
- Lieberman, A. P., Robitaille, Y., Trojanowski, J. Q., Dickson, D. W. & Fischbeck, K. H. 1998 Polyglutamine-containing aggregates in neuronal intranuclear inclusion disease. *Lancet* **351**, 884.
- Lucassen, P. J., Chung, W. C. J., Kamphorst, W. & Swaab, D. F. 1997 DNA damage distribution in the human brain as shown by *in situ* end labelling; area-specific differences in ageing and Alzheimer disease in the absence of apoptotic morphology. *J. Neuropathol. Exp. Neurol.* **56**, 887–900.
- Mangiarini, L. (and 10 others) 1996 Exon 1 of the HD gene with an expanded CAG repeat is sufficient to cause a progressive neurological phenotype in transgenic mice. *Cell* **87**, 493–506.
- Mengual, E., Arizti, P., Rodrigo, J., Giménez-Amaya, J. M. & Castaño, J. G. 1996 Immunohistochemical distribution and electron microscopic subcellular localisation of the proteasome in the rat CNS. *J. Neurosci.* **16**, 6331–6341.
- Ordway, J. M. (and 11 others) 1997 Ectopically expressed CAG repeats cause intranuclear inclusions and a progressive late onset neurological phenotype in the mouse. *Cell* **91**, 753–763.
- Papp, M. I. & Lantos, P. L. 1994 The distribution of oligodendroglial inclusions in multiple system atrophy and its relevance to clinical symptomatology. *Brain* **117**, 235–243.
- Paulson, H. L., Das, S. S., Crino, P. B., Perez, M. K., Patel, S. C., Gotsdiner, D., Fischbeck, K. H. & Pittman, R. N. 1997a Machado-Joseph disease gene product is a cytoplasmic protein widely expressed in brain. *Ann. Neurol.* **41**, 453–462.
- Paulson, H. L., Perez, M. K., Trotter, Y., Trojanowski, J. Q., Subramony, S. H., Das, S. S., Vig, P., Mandel, J. L., Fischbeck, K. H. & Pittman, R. N. 1997b Intranuclear inclusions of expanded polyglutamine protein in spinocerebellar ataxia type 3. *Neuron* **19**, 333–344.
- Perutz, M. F., Johnson, T., Suzuki, M. & Finch, J. T. 1994 Glutamine repeats as polar zippers: their possible role in inherited neurodegenerative diseases. *Proc. Natl Acad. Sci. USA* **91**, 5355–5358.
- Portera-Cailliau, C., Hedreen, J. C., Price, D. L. & Koliatsos, V. E. 1995 Evidence for apoptotic cell death in Huntington disease and excitotoxic animal models. *J. Neurosci.* **15**, 3775–3787.
- Robitaille, Y., Lopes-Cendes, I., Becher, M., Rouleau, G. & Clark, A. W. 1997 The neuropathology of CAG repeat diseases: review and update of genetic and molecular features. *Brain Pathol.* **7**, 877–881.

- Roizin, L., Stellar, S. & Liu, J. C. 1979 Neuronal nuclear–cytoplasmic changes in Huntington's chorea: electron microscope investigations. *Adv. Neurol.* **23**, 95–122.
- Ross, C. A., Becher, M. W., Coloner, V., Engelender, S., Wood, J. D. & Sharp, A. H. 1997 Huntington's disease and dentatorubral–pallidolusian atrophy: proteins, pathogenesis and pathology. *Brain Pathol.* **7**, 1003–1017.
- Scherzinger, E., Lurz, R., Turmaine, M., Mangiarini, L., Hollenbach, B., Hasenbank, R., Bates, G. P., Davies, S. W., Lehrach, H. & Wanker, E. E. 1997 Huntingtin encoded polyglutamine expansions form amyloid-like protein aggregates *in vitro* and *in vivo*. *Cell* **90**, 549–558.
- Schmidt, T. (and 10 others) 1998 An isoform of ataxin-3 accumulates in the nucleus of neuronal cells in affected brain regions of SCA3 patients. *Brain Pathol.* **8**, 669–681.
- Skinner, P. J., Koshy, B. T., Cummings, C. J., Klement, I. A., Helin, K., Servadio, A., Zoghbi, H. Y. & Orr, H. T. 1997 Ataxin-1 with an expanded glutamine tract alters nuclear matrix-associated structures. *Nature* **389**, 971–974.
- Sotrel, A., Paskevitch, P. A., Kiely, D. K., Bird, E. D., Williams, R. S. & Meyers, R. H. 1991 Morphometric analysis of the prefrontal cortex in Huntington's disease. *Neurology* **41**, 1117–1123.
- Spillantini, M. G., Crowther, R. A., Jakes, R., Cairn, N. J., Lantos, P. L. & Goedert, M. 1998 Filamentous α -synuclein inclusions link multiple system atrophy with Parkinson's disease and dementia with Lewy bodies. *Neurosci. Lett.* **251**, 205–208.
- Trottier, Y., Devys, D., Imbert, G., Sadou, F., An, I., Lutz, Y., Weber, C., Agid, Y., Hirsch, E. C. & Mandel, J.-L. 1995 Cellular localisation of the Huntington's disease protein and discrimination of the normal and mutated forms. *Nature Genet.* **10**, 104–110.
- Turmaine, M., Raza, A. S., Mahal, A., Mangiarini, L., Bates, G. P. & Davies, S. W. 1999 Non apoptotic dark cell degeneration in a transgenic mouse model of Huntington's disease. *Nature*. (Submitted.)
- Vonsattel, J.-P. G. & DiFiglia, M. 1998 Huntington disease. *J. Neuropathol. Exp. Neurol.* **57**, 369–384.
- Vonsattel, J.-P. G., Meyers, R. H., Stevens, T. J., Ferrante, R. J., Bird, E. D. & Richardson, E. P. 1985 Neuropathological classification of Huntington's disease. *J. Neuropathol. Exp. Neurol.* **44**, 559–577.
- Warrick, J. M., Paulson, H. L., Gray-Board, G. L., Bui, Q. T., Fischbeck, K. H., Pittman, R. N. & Bonini, N. M. 1998 Expanded polyglutamine protein forms nuclear inclusions and causes neural degeneration in *Drosophila*. *Cell* **93**, 939–949.
- Wyllie, A. H., Kerr, J. F. R. & Currie, A. R. 1980 Cell death: the significance of apoptosis. *Int. Rev. Cytol.* **68**, 251–305.
- Young, A. B. 1998 Huntington's disease and other trinucleotide repeat disorders. In *Molecular neurology* (ed. J. B. Martin), pp. 35–54. New York: Scientific American.

BIOLOGICAL
SCIENCES



THE ROYAL
SOCIETY

PHILOSOPHICAL
TRANSACTIONS
OF

BIOLOGICAL
SCIENCES



THE ROYAL
SOCIETY

PHILOSOPHICAL
TRANSACTIONS
OF